

TREATMENT OF A PRESSURE WOUND WITH AN ENZYME ALGINOGEL®

Kasia Huisman, Wound and Dermatology Nurse,
BrabantZorg Oss, The Netherlands

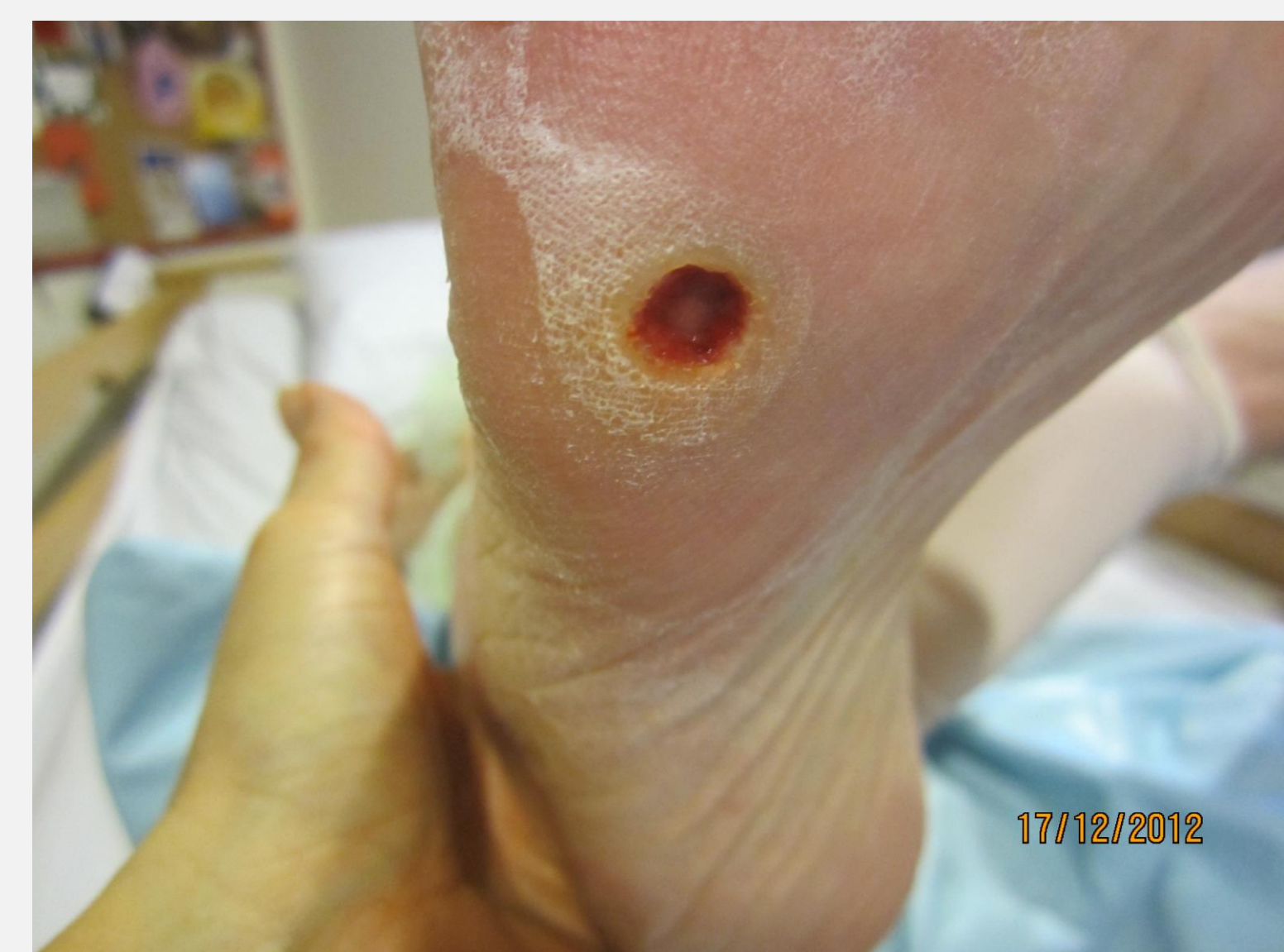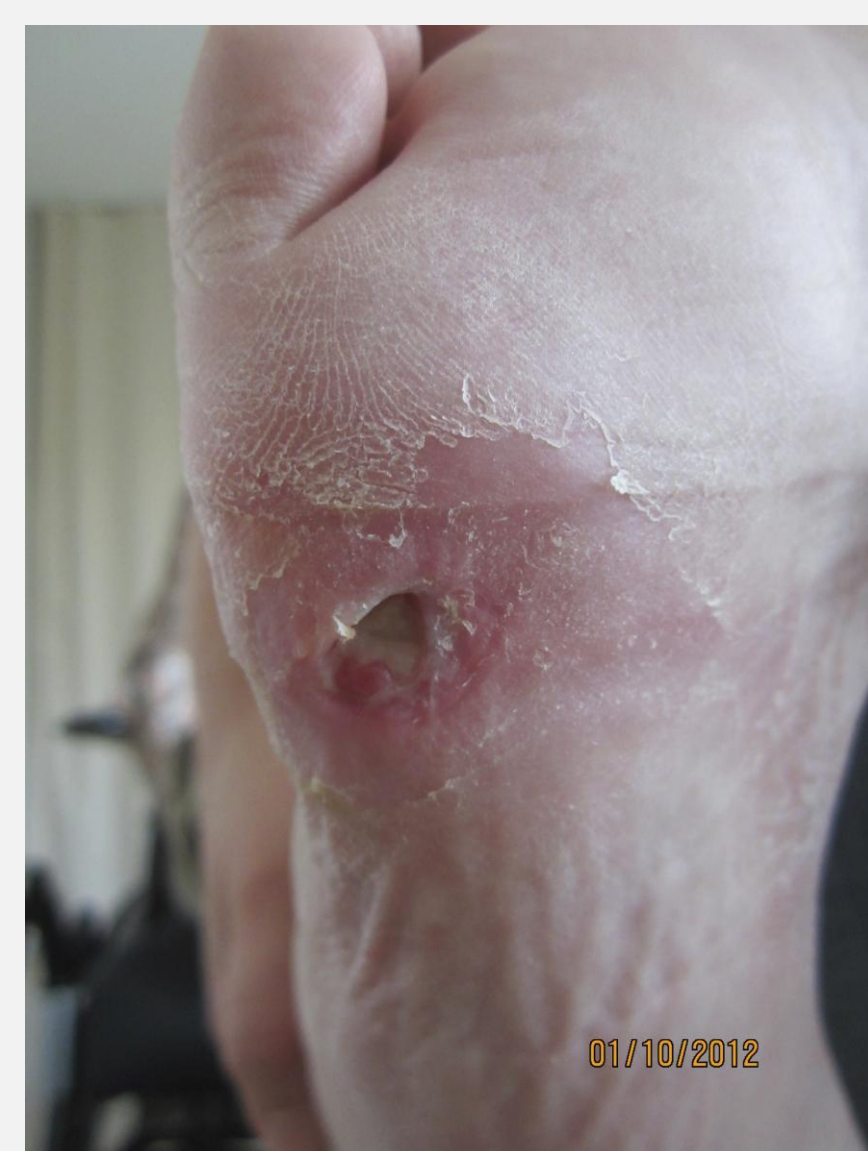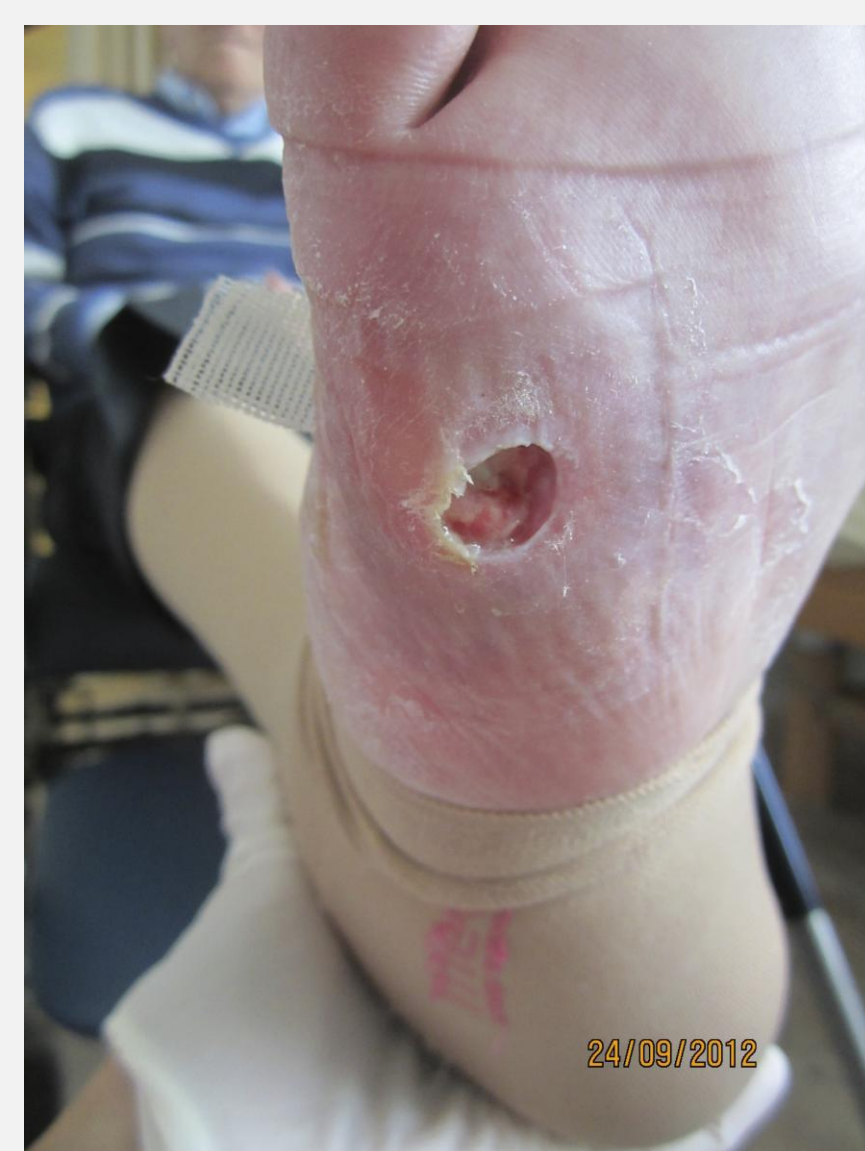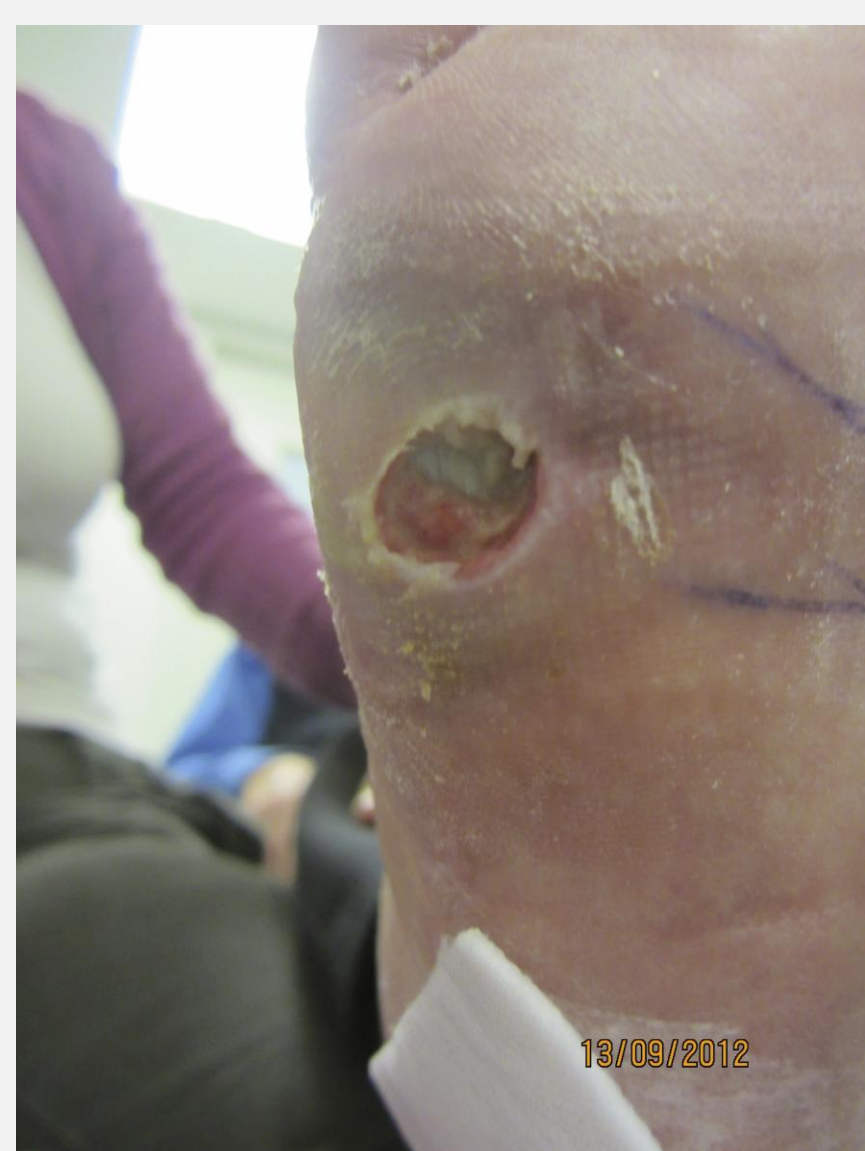
INTRODUCTION

The aim of this case was to investigate whether an enzyme alginogel® could be integrated in the current wound protocol based on the efficiency of the enzyme alginogel® in treating yellow wounds.

TREATMENT

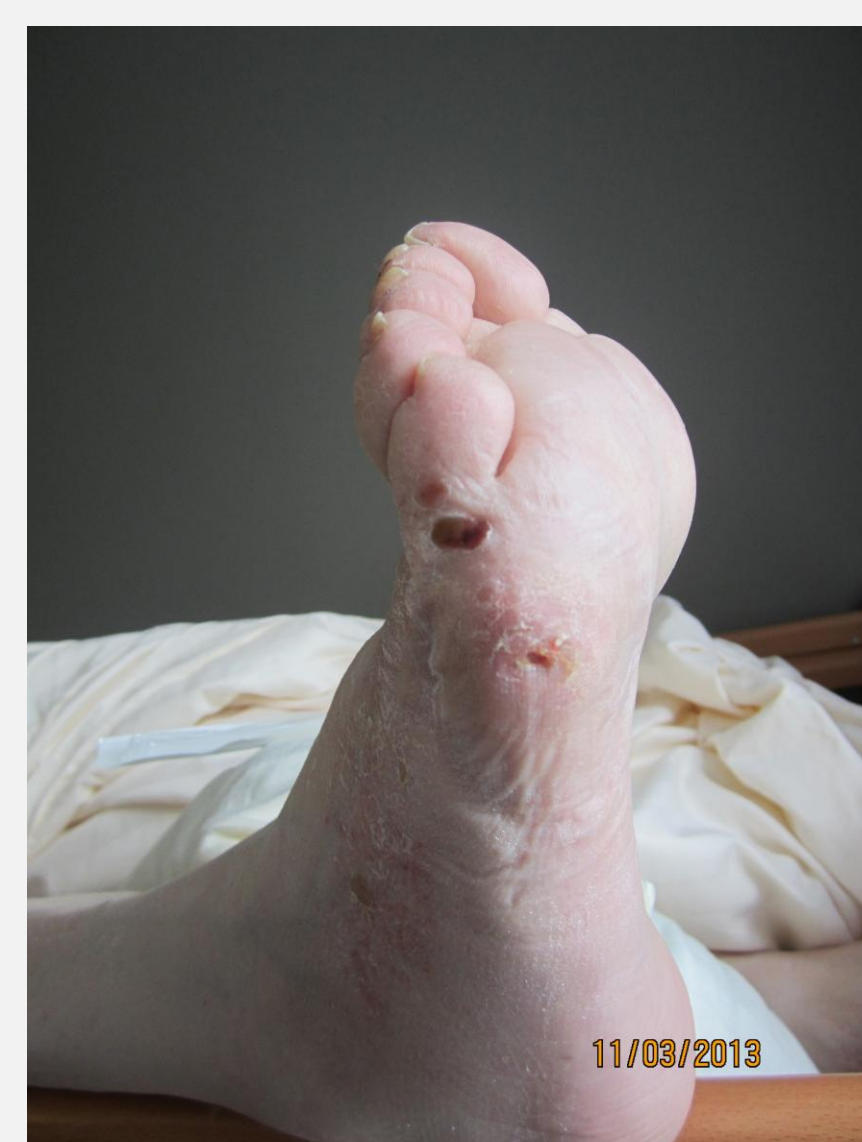
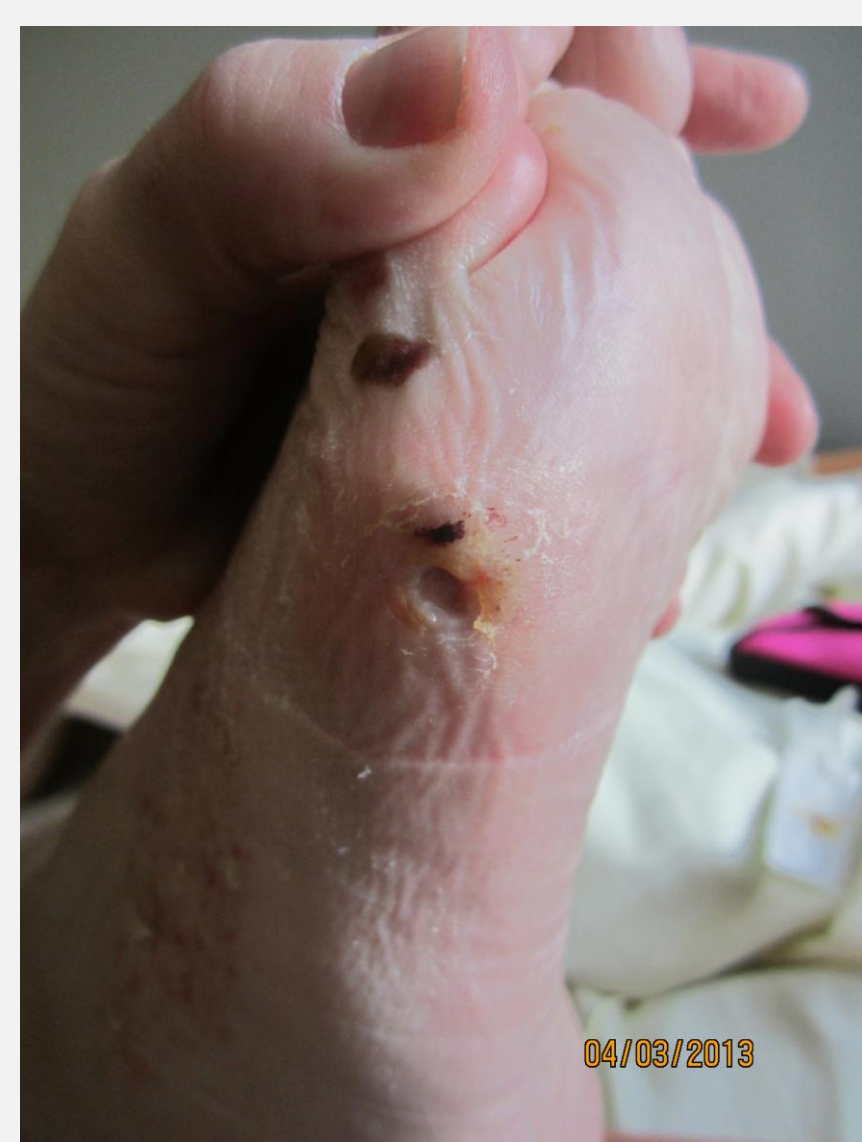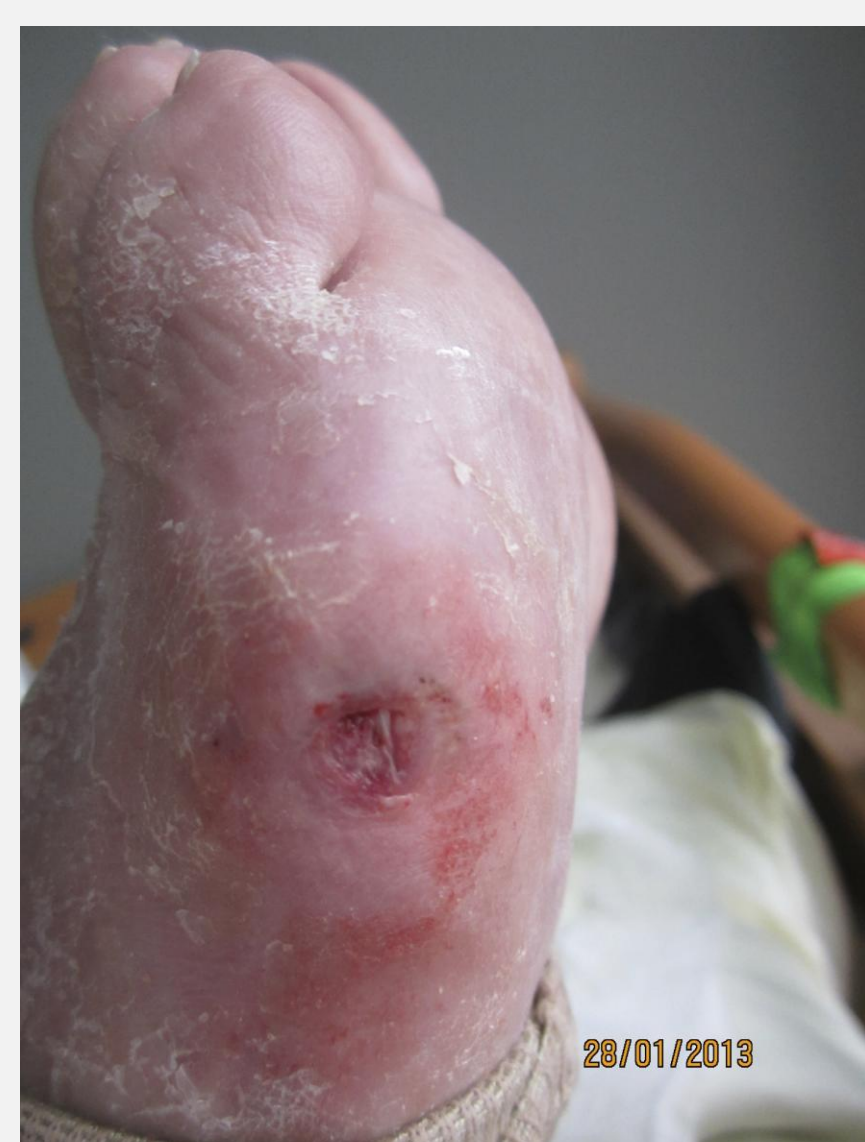A 82-year-old man suffering from Alzheimer's, poor vision, cardiac problems, hypertension as well as Strumpell disease developed a pressure wound on the lateral plantar surface of the foot. This was caused by foreign material inside his orthopaedic shoe.

The wound was closed, having formed a pocket containing pus. Two days later, the wound became infected and the patient was treated with antibiotics. The wound was opened and debrided up to the fascia. The wound was then further treated with regular cleansing and application of an enzyme alginogel® to the wound, and was covered by a secondary dressing. Additionally, an offloading device was also put in place.



RESULTS

After one week, the wound was clean and filled with granulation tissue. After 2 weeks, the wound had reduced by 50% in size and after 4 weeks, the wound had closed completely.



CONCLUSIONS

This case, together with results from other cases, has shown that enzyme alginogels® are highly efficient in the treatment of yellow wounds and are thus integrated fully in our local wound protocol.